

## Role of radiology and fungal culture in diagnosis of allergic fungal sinusitis

<sup>1</sup>Umar Ali, <sup>2</sup>Dr Reeta Rani, <sup>3</sup>Dr Azhar Farooq, <sup>4</sup>Taimoor Ghori, <sup>5</sup>Khurram Ali, <sup>6</sup>Marwa Riaz

Submission: 20 January 2026 | Acceptance: 11 February 2026 | Publication: 10 March 2026,

<sup>1</sup>PIMS Islamabad

<sup>2</sup>Associate Professor Diagnostic Radiology Shaheed Mohtarma Benazir Bhutto Medical College Lyari Karachi

<sup>3</sup>Consultant ENT, DHQ hospital Sheikhpura

<sup>4</sup>PIMS Islamabad

<sup>5</sup>PIMS Islamabad

<sup>6</sup>UHS Lahore

### ABSTRACT

**Objective:** Investigate the role of serrated turbinates, radiographic abnormalities, and existing literature in aiding the diagnosis of Allergic Fungal Sinusitis (AFS).

**Study Design:** Cross-sectional study

**Place and duration of study:** Ear Nose Throat Department Combined Military Hospital, Rawalpindi Pakistan from Jan 2020 to July 2023.

**Methodology:** 120 individuals who received computerized tomography examinations at our facility during January 2020 to July 2023 were included in our study. Hospital ethical review committee certificate number is 423, dated 20 February 2023. Patients identified as having Allergic Fungal Sinusitis (AFS) following tests for allergies and/or fungi were placed in the first group, while those identified as having rhinosinusitis (other than AFS) were placed in the second group. The CT scan pictures were examined for polyps, bone degradation, serrated appearance of turbinate and CT hyper-density.

**Results:** When comparing the radiological characteristics of AFS and non-AFS, it was discovered that the presence of a serrated turbinate was significantly more prevalent in AFS ( $p < 0.05$ ). There were no differences between the groups in the terms of bone degradation, polyp presence, or CT hyper-density ( $p > 0.05$ ).

Total number of subjects in this study was 120 who were equally split between male and female met the inclusion criteria for our study. Their mean age was 36.81 years (18-63 years of age range) and SD of 11.24 years. There are 120 patients; 86 (72%) are AFS (-ve) and the 34 (28%) are the AFS (+ve) individuals. Out of them, 19 patients (16%) of the AFS (+ve) patients were female, whereas 15 patients (12%) were male.

**Conclusion:** Our research revealed that the presence of serrated turbinates may serve as a helpful radiological signal in the diagnosis of AFS. In order to properly assess bone erosion in relation to other structural and morphological changes in the structure of bone, it is important to specify the measurements of bone density for sinus opacification.

**Keywords:** Allergic fungal sinusitis, Bone erosion, Fungal culture, Radiology.

### INTRODUCTION:

Previously thought to be rare, fungal sinusitis has recently been observed more frequently, especially in countries with warmer temperatures like the Southern United States and

Australia. Five subtypes make up fungal sinusitis classification, which has been changed during past 20 years<sup>1-3</sup>. While fungal mycetoma and allergic fungal sinusitis (AFS) were categorized as the fungal sinusitis (non-invasive), the invasive group includes acute invasive fungal sinusitis, chronic invasive fungal sinusitis, and chronic granulomatous invasive fungal sinusitis<sup>1, 4</sup>. There are various clinical and radiologic characteristics among these five subtypes<sup>1</sup>. Each variety also has varied prognoses and treatment plans. To separate fungal sinusitis subtypes from subtypes of bacterial sinusitis and to begin accurate, prompt treatment and diagnosis, it is crucial to differentiate them using their unique radiological features<sup>1, 5</sup>.

In 1976, a study that included formation of nasal mucosal crust, nasal polyposis that resembled *Aspergillus* and sinusitis isolation from cultures of sinus established a picture clinically of allergic bronchopulmonary aspergillosis that gave rise to the concept of AFS<sup>6</sup>. In 1981, Millar et al. classified the same clinical presentation as allergic aspergillosis of paranasal sinuses, and in 1983, Katzenstein and others. classified it as allergic aspergillus sinusitis<sup>7, 8</sup>. The pathology, which was first described by Robson and others. and given the name AFS (allergic fungal sinusitis) to indicate that it could be brought on by the non-aspergillus fungus, is anew recognized illness that be located typically or seen in people with allergies also is distinct from the other kinds of the sinusitis<sup>9</sup>. Resulting, that the AFS, which is the most frequent kind of fungal sinusitis, the Ig-E mediated hyper-sensitivity reaction to the fungal components rather than a mucosal infection<sup>8, 10</sup>.

The tests of positive allergy, distinctive CT-scan features, nasal polyposis, the existence of the eosinophilic mucus, and the identification of fungal culture are the criteria of diagnosis for AFS that Kuhn and Bent established in 1994. Though, as noted by authors, that there should initially be suspicion that patient has AFS<sup>5</sup>. Heterogeneous mucin-induced regions in paranasal sinuses on the CT scans which were considered as generally characterizing aspects of condition in later research, despite the fact that they remained not unique to AFS<sup>11, 12</sup>. It is definite that the combined MRI and CT results have made available the radiographic appearance which is highly specific for the AFS. In MRI, central hypointense appearance in sequence T1W, existence of a peripheral signal and central signal gap increase in the sequence T2W which are substantial for the AFS when compared with the subtypes of fungal sinusitis (invasive)<sup>13</sup>. There are, however, recent perspectives that claim that the diagnosis of AFS cannot be made solely on the basis of radiological data<sup>14</sup>.

Despite the fact that the Kuhn and Bent criteria of diagnosis for AFS are very helpful, recent research has revealed that this disease is much more prevalent than anticipated in some regions of the world. As a result of the rise in AFS diagnoses, it may be necessary to re-evaluate the radiological diagnostic criteria<sup>5</sup>. In our investigation, we sought to determine whether there were any differences in the radiological findings between AFS and non-AFS patients and whether the existence of the serrated turbinate, a novel radiological outcome that may aid in diagnosis of AFS, was present.

## METHODOLOGY

This Cross-sectional study was conducted at Ear Nose Throat Department, Combined Military Hospital Rawalpindi Pakistan from Jan 2020 to July 2023. Acceptance from Hospital Ethical Committee was acquired on a certificate, which was carried out in conformity with the ethical standards outlined. Hospital ethical review committee certificate number is 423, dated 20 February 2023. Out of 186 patients who experienced a paranasal sinus CT exam at our facility from January 2020 to July 2023 with a preliminary sinusitis diagnosis, 120 participated in our study. Consent from the examination subjects was taken prior to filling the questionnaire for study.

### Inclusion Criteria:

Patients who underwent testing for allergies and/or fungi.

Patients diagnosed with allergic fungal sinusitis (AFS), who diagnosed with rhinosinusitis unrelated to AFS.

#### Exclusion Criteria:

A total of 66 patients were excluded from the study. This included 26 patients under the age of 18, 32 patients with a history of paranasal sinus surgery, and 8 patients with invasive or mass pathology. These exclusions were made to maintain consistency and reliability within the study population, facilitating more accurate analysis and interpretation of the results.

The General Electric IQTM 32-Detector Spiral MSCT device was used for CT scans. The axial plane photographs were assessed retroactively by a radiologist and an otolaryngologist with knowledge of radiological anatomy, together with coronal and sagittal reformat images. On CT images, the existence of polyps, the presence of bone degradation, the presence of serrated turbinate morphology, and hyper-density in the sinus are examined Figure 1.

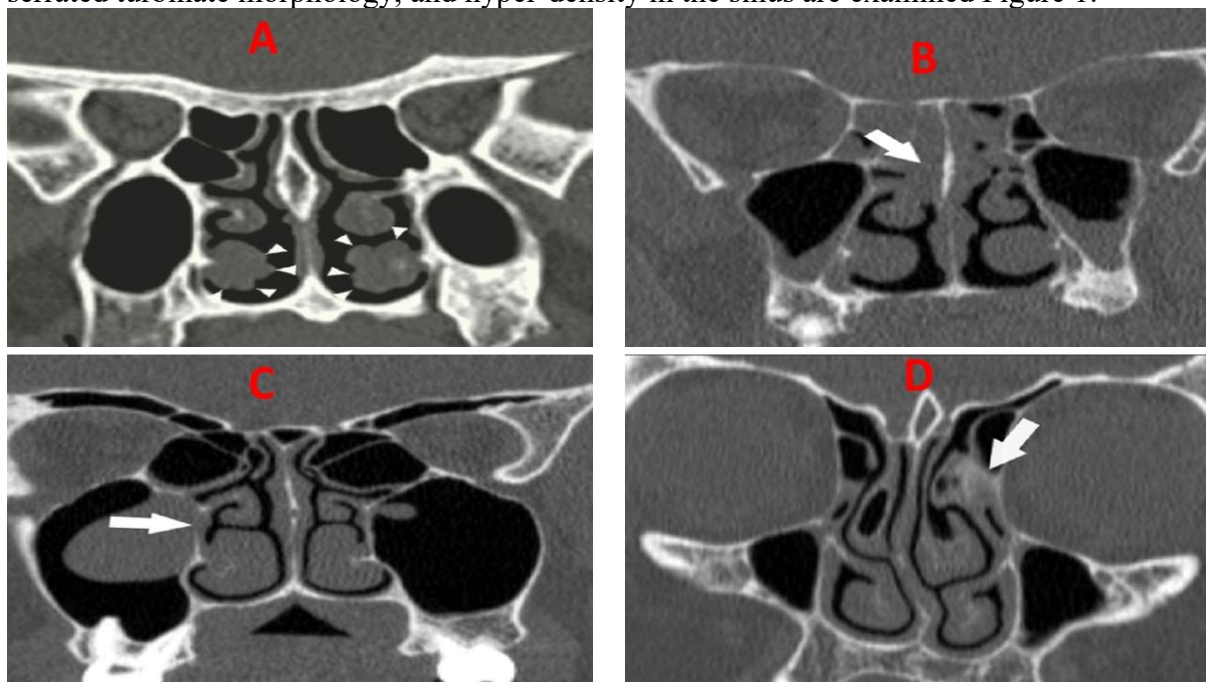


Figure 1: A=Serrated turbinate, B=Polypoid lesion, C=Bone erosion, and D=Hyperdense lesion.

#### Statistical Analysis

The statistical package for the social sciences (SPSS), version 26, was used to examine the data. The Shapiro-Wilk test was used to assess the distribution of variables. In this test, variables were found not to be distributed usually. The chi-square test was also used for evaluation of categorical data. Threshold for significance is 0.05.

#### RESULTS

120 adult patients between the ages of 18 and 63 who were equally split between male and female met the inclusion criteria for our study. The age distribution is normal. There are 120 patients; 86 (72%) are AFS (-ve) and the 34 (28%) are the AFS (+ve) individuals. Out of them, 19 patients (16%) of the AFS (+ve) patients were female, whereas 15 patients (12%) were male. Polyp formation, gender, serrated concha appearance, hyperintensity and bone erosion on CT are compared between AFS (+ve) and AFS (-ve) individuals. Only the serrated concha morphology on CT ( $p=0.05$ ) was found to be statistically significant among the characteristics Table 1. Patients with positive and negative serrated concha are evaluated for polyp growth, bone erosion, and hyper-density on CT. Patients with serrated concha

positivity and negativity were shown to differ statistically. However, there was no statistically significant difference in bone erosion and hyper-density characteristics on CT between positive and negative patients Table 2.

Table 1: Comparison of positive and negative AFS patients. (n=

	AFS		p
	Negative (%)	Positive (%)	
Male	37.5	12.5	p>0.05
Female	34.2	15.8	
<b>Polyp</b>			
Negative	50	15.8	p>0.05
Positive	21.7	12.5	
<b>Serrated Turbinate</b>			
Negative	67.5	12.5	p<0.05
Positive	4.2	15.8	
<b>Bone Erosion</b>			
Negative	70.8	26.5	p>0.05
Positive	0.8	1.7	
<b>Hyper-density</b>			
Negative	66.2	24.2	p>0.05
Positive	5	4.2	

Table 2: Comparison of morphology of serrated concha on CT. (n=

	Serrated		p
	Negative (%)	Positive (%)	
<b>Erosion</b>			
Negative	79.2	18.3	p=0.1
Positive	0.8	1.7	
<b>Polyp</b>			
Negative	56.7	9.2	p=0.021
Positive	23.3	10.8	
<b>Hyper-density</b>			
Negative	72.5	18.3	p=0.6
Positive	7.5	1.7	

## DISCUSSION

AFS is a kind of chronic sinusitis that is characterized by type I, IgE-mediated hypersensitivity to fungi, the existence of the eosinophilic mucus with the fungal hyphae in sinuses, and chronic sinusitis<sup>15</sup>. Because of inflammation of eosinophil-predominant, and inflammatory responses to diverse species of fungus, pathological findings in AFS can vary<sup>16</sup>. The four fungi that are most frequently observed in AFS are *Alternaria*, *Aspergillus*, *Curvularia*, *Bipolaris*. According to several studies, the prevalence of AFS among people with chronic sinusitis ranges from 4 to 24 percent, and in temperate areas, it may even be greater<sup>17</sup>.

Despite the fact that AFS is comparatively new condition, there are several researches in literature, particularly on aspects of the radiological imaging. The studies offer a wealth of knowledge on the MRI and CT pictures in the AFS<sup>2, 4</sup>. The major and the minor criteria of Bent and the Kuhn criteria are utilized to diagnose the AFS. History of the type 1 hypersensitivity determined through in-vitro test or a skin test, the nasal polyposis, findings of characteristic CT scan (the areas of the serpiginous hyper-attenuation), the existence of eosinophilic mucin deprived of signs of invasion, and the existence of fungal cells in surgically removed tissue are the main requirements. Patients must satisfy all of the key diagnostic requirements, with the exception of a positive fungal cell culture. Minor requirements include peripheral eosinophilia, Charcot-Leyden crystals, and unilateral disease predominance. Minor requirements are diagnostic but do not support the diagnosis<sup>5</sup>. Although CT can also be used to diagnose sinusitis and show bone degradation, it was shown that it was insufficient to detect the cause of the sinusitis<sup>18</sup>. While "ground-glass", "serpiginous" or "starry-sky" patterns, often known as "double-density" pictures in the CT scans, which are frequently linked to the AFS, it had been claimed that the look is as well present in further fungal illnesses.<sup>19</sup>In later studies, the three specific results (high *Aspergillus*-directed IgE antibody titers, hyper-attenuation foci in sinuses on the CT scan, and the nasal polyps) were recognized as specific and consistent indicators for pre-operative diagnosis of the AFS. According to Bent and Kuhn, all AFS patients displayed polyposis and hyper-attenuation on their CT scans<sup>5</sup>. According to some reports, nasal polyps are not connected to allergies but they could be connected to AFS.<sup>2</sup> The existence of the heavy metal deposits (such as manganese and iron) and precipitation of calcium salt in allergic fungal

mucin is most likely reason for the hyper-density in CT<sup>11</sup>. Hyper-attenuation and the development of polyps were not statistically significant in our investigation. Although the literature analysis referred to the CT finding as hyper-density, no study provided a definite Hounsfield Unit (HU) number. Due to content of inflammatory sinus of the soft tissue density, we are unable to utilize the phrase "sinus opacification" that we previously used to assess sinus radiography. We believe that this proportionate discrepancy may be caused by the different language usage; to address this, it could be helpful to provide particular HU values in future investigations.

Radiological imaging findings still include bone erosion and growth even though AFS is recognized as a non-invasive sinusitis<sup>20</sup>. According to numerous research, bone degradation occurs between 20 and 80 percent of the time<sup>21, 22</sup>. It is hypothesized that as mucin production in the sinus rises, decalcification, mucocele development, and bone remodeling may take place in the paranasal sinus that is affected<sup>20</sup>. The presence of mucin and localized inflammatory alterations may cause the sinuses to expand and remodel<sup>23</sup>. While bone erosion is not always indicative of an invasive disease, resorption of local bone is far more frequent in the AFS than in the other types of chronic sinusitis. It might result from mucin's pressure-related actions<sup>23</sup>. Therefore, it is inappropriate to regard bone erosion as the sign of the AFS in this situation. In fact, as the Kuhn and Bent noted, it is regrettably impossible to become disagree with researchers who said that due to the disease's novelty, there are several misconceptions about AFS and that misdiagnosis of the condition is common in spite of intervening 27 years<sup>5</sup>. In our investigation, the frequency of the bone degradation was likewise not statistically substantial. This might be because we excluded remodeling from our study's definition of erosion.

Our attention was drawn to serrated turbinate look, one of coincidental results in the paranasal sinus topographies that El Khateeb and Zain-Al-Abdeen discussed in their study<sup>24</sup>. Serrated turbinate look may be mistaken for the mucosa's cobblestone appearance while discussing serrated turbinate with professionals. However, we found that this morphology was not identified in the literature as a radiological finding. Surprisingly, when we added the serrated turbinate morphology in our investigation, we discovered a statistical correlation between this morphology and the AFS (where  $p < 0.05$ ). Though, because our study primarily focuses on the AFS, more extensive research is required to determine how the serrated turbinate shape relates to other subtypes of allergic rhinitis and fungal sinusitis.

Like Pillai et al., we currently believe that CT imaging is insufficient on its own to reliably diagnose one of the subtypes of the fungal sinusitis, possibly just allowing us to distinguish it from the non-fungal sinusitis.<sup>14</sup> Additionally, it has been noted that combining CT and MRI data might produce a radiological look that is extremely specific for the AFS<sup>3</sup>.

Our research has some drawbacks. Since our study was retrospective in nature and MRI pictures of the patients were not available, they were not included in it. Another limitation of our study is the small number of patients with AFS who received a diagnosis. This study is the first to examine the relationship between paranasal serrated turbinate shape and AFS, and more investigation is required before larger patient populations can be evaluated.

## CONCLUSION

A fungal infection in immune-competent people must be suspected to diagnose the AFS, and it must be evaluated radiologically, microbiologically, histopathologically, and immunologically with the examination of ENT. This is true even though AFS is a clinical entity that have only described recently. In cases treated as AFS in our investigation, no diagnostic criteria were discovered, which is consistent with the literature. We contend that in order to properly establish the value of the findings radiologically, particularly the serrated

turbinate, for the diagnosis of the AFS, we require significant and impartial research.

## ACKNOWLEDGEMENTS

We would like to thank all of our seniors and our colleagues who helped us in compiling this Study, helped in collecting data and did the relevant literature search.

## LIMITATIONS

The study has several limitations that should be acknowledged. The lack of MRI data and the limited availability of patients diagnosed with allergic fungal sinusitis (AFS) further constrain the comprehensiveness and statistical power of the analysis. Given the heterogeneity of AFS presentation and the subjective interpretation of radiological images, interpretation bias may have influenced the results. These limitations underscore the need for larger, multi-center studies with longitudinal data and comprehensive radiological assessments to advance our understanding of allergic fungal sinusitis diagnosis and management.

## CONFLICT OF INTEREST

None

## FUNDING

None.

## References

1. Chen A, Pietris J, Bacchi S, Chan W, Psaltis AJ, Selva D, et al. Imaging Features of Invasive Fungal Rhinosinusitis: A Systematic Review. *Can Assoc Radiol J*. 2024.
2. Scadding GK, Durham SR, Mirakian R, Jones NS, Drake-Lee AB, Ryan D, et al. BSACI guidelines for the management of rhinosinusitis and nasal polyposis. *Clin Exp Allergy*. 2008;38(2):260-275.
3. Roland LT, Humphreys IM, Le CH, Babik JM, Bailey CE, Ediriwickrema LS, et al., editors. Diagnosis, Prognosticators, and Management of Acute Invasive Fungal Rhinosinusitis: Multidisciplinary Consensus Statement and Evidence-Based Review with Recommendations. *Int Forum Allergy Rhinol*. 2023;13(9):1615-1714.
4. Alghonaim Y, Alfayez A, Alhedaithy R, Alsheikh A, Almalki M. Recurrence pattern and complication rate of allergic fungal sinusitis: a 10-year tertiary center experience. *Int J Otolaryngol*. 2020;(1):1-6.
5. Kupferberg SB, Bent III JP, Kuhn FA. Prognosis for allergic fungal sinusitis. *Otolaryngol—Head and Neck Surg*. 1997;117(1):35-41.
6. Shah A, Panjabi C. Allergic bronchopulmonary aspergillosis: a perplexing clinical entity. *Allergy Asthma Immunol Res*. 2016;8(4):282-297.
7. Panjabi C, Shah A. Allergic Aspergillus sinusitis and its association with allergic bronchopulmonary aspergillosis. *Asia Pac Allergy*. 2011;1(3):130-7.
8. Chakrabarti A, Kaur H. Allergic aspergillus rhinosinusitis. *J Fungi*. 2016;2(4):32.
9. Robson JM, Hogan PG, Benn RA, Gatenby PA. Allergic fungal sinusitis presenting as a paranasal sinus tumour. *Aust N Z J Med* 1989;19: 351- 3.
10. Soler ZM, Schlosser RJ. The role of fungi in diseases of the nose and sinuses. *Am J Rhinol Allergy* 2012;26:351-358.
11. Midyett FA, Mukherji SK, Midyett FA, Mukherji SK. Allergic fungal sinusitis. *Skull Base Imaging: The Essentials*. 2020:209-12.
12. Zinreich SJ, Kennedy DW, Malat J, Curtin HD, Epstein JI, Huff LC, et al. Fungal sinusitis: diagnosis with CT and MR imaging. *Radiology*. 1988;169(2):439-44.
13. Athre RS, Marple BF. Allergic Fungal Rhinosinusitis—Surgical Management. *Rhinologic and Sleep Apnea Surgical Techniques*: Springer; 2007. p. 111-117.

14. Pillai S, Bhandarkar AM, Nair SS, Jha AT, Ramaswamy B, Al-Abri R. A radiological profile of fungal sinusitis. *Asian J Pharm Clin Res* 2017;10:331-4.
15. Gan EC, Thamboo A, Rudmik L, Hwang PH, Ferguson BJ, Javer AR. Medical management of allergic fungal rhinosinusitis following endoscopic sinus surgery: an evidence-based review and recommendations. *Int Forum Allergy Rhinol*. 2014;4(9):702–15.
16. Issa MJA, Oliveira VRRd, Nunes FB, Vasconcelos LOG, Souza LFB, Cherobin GB, et al. Prevalence of respiratory epithelial adenomatoid hamartomas (REAH) associated with nasal polyposis: an epidemiological study—how to diagnose. *Braz J of Otorhinolaryngol*. 2022;88:57-62.
17. Xu T, Guo X-T, Zhou Y-C, Zhou Q, Wang Y-F. Consideration of the Clinical Diagnosis of Allergic Fungal Sinusitis: A Single-Center Retrospective Study. *Ear, Nose Throat J*. 2023.
18. Meng Y, Zhang L, Piao Y, Lou H, Wang K, Wang C. The use of magnetic resonance imaging in differential diagnosis of allergic fungal sinusitis and eosinophilic mucin rhinosinusitis. *J Thorac Dis*. 2019;11(8):3569-3577.
19. Montone KT. Pathology of fungal rhinosinusitis: a review. *Head Neck Pathol*. 2016;10(1):40-46.
20. Manila N, Nair M, Liang H. Incidental Findings of Asymptomatic Fungal Infection. *Case Rep Dent*. 2022;2022.
21. Chua AJ, Jafar A, Luong AU. Update on Allergic Fungal Rhinosinusitis. *Ann Allergy Asthma & Immunol*. 2023;131(3):300-306.
22. Erami M, Aboutalebian S, Hezaveh SJH, Ghazvini RD, Heravi MM, Jafari Y, et al. Microbial and clinical epidemiology of invasive fungal rhinosinusitis in hospitalized COVID-19 patients, the divergent causative agents. *Med Mycol*. 2023;61(3):myad020.
23. Burnham AJ, Magliocca KR, Pettitt-Schieber B, Edwards TS, Marcus S, DelGaudio JM, et al. Intermediate invasive fungal sinusitis, a distinct entity from acute fulminant and chronic invasive fungal sinusitis. *Ann Otol Rhinol Laryngol*. 2022;131(9):1021-1026.
24. Alassaf MS, Alolayan A, Almuzaini E, Masoudi AA, Alturki K, Alsaeedi AK, et al. Prevalence and Characteristics of the Maxillary Sinus Septa in a Saudi Arabian Subpopulation: A Retrospective Cone Beam Computed Tomography (CBCT)-Based Study. *Cureus*. 2023;15(10).